

EVALUATION OF THE EFFECTIVENESS OF TREATMENT FOR HAND BONE FRACTURES USING THE ILIZAROV MINI DEVICE

Suvonov Uktam Kholmuradovich¹, Urokov Shokhijahon Zayniddinovich²,
Kholmurodov Furqat Nasim o'g'li³, Kuziyev Siddiqjon Rifat o'g'li⁴

Senior Student¹, student^{2,3,4}

Tashkent State Medical University^{1,3,4}

Tashkent Kimyo International University²

Annotation: The work shows that the use of the device allowed achieving early consolidation of bone tissue, reducing the risk of post-traumatic contractures and reducing the rehabilitation period. We assessed the treatment outcomes as follows: - good - in 37 (77.1%), - satisfactory - in 10 (20.8%) and - unsatisfactory - in 1 (2.1%) patient. The reason for the unsatisfactory results is the secondary infected wounds developed around the spoke, so the device was removed and a plaster cast was used.

Key words: hand, tubular bones, fractures, transosseous osteosynthesis, Ilizarov mini-apparatus, treatment.

Among the musculoskeletal system injuries, hand injuries are widespread, and fractures of the bones of the hand and paws occupy a leading place. Taking into account the complexity of the anatomical structure of the hand, the choice of treatment method is very important for restoring functionality [1-4,14,17]. The hand and paw perform static, dynamic and sensory functions. Therefore, any damage to it significantly reduces the professional and social capabilities of a person. Among the musculoskeletal system fractures, fractures of the phalanges of the hand and paws are the most common type of injuries, accounting for 23-40% of the total [1, 2, 8].

The high frequency of injuries of the metacarpal bones of the hand and paw, the variety of open fractures and their combination with tendon injuries, necessitate the creation of a stable fixation that ensures stable fixation of bone fragments and early and full functioning of adjacent joints [3, 5, 6]. In this regard, interosseous osteosynthesis with an external fixation device deserves special attention, since it allows for the optimal course of the reparative regeneration process of bone tissue and the fulfillment of all the conditions necessary for the rapid functional recovery of the injured segment [16, 17].

However, despite this, interosseous osteosynthesis with external fixation devices is relatively rarely used in patients with fractures of the carpal bones - it is used mainly for intra-articular fractures of the base of the I-th metacarpal bone (Bennett and Rolando fractures) [9,10,13]. Among all injuries, injuries of the carpal bones account for 30-60%. The frequency of loss of work activity in these injuries is up to 32.2%, and disability is up to 25%. In our opinion, this is due to the significant technical difficulties of using external fixation devices in fractures of the carpal bones [5,7,8,14].

Purpose: To improve the results of treatment of patients using the Ilizarov mini-fixator in the treatment of fractures of the bones of the paw.

Material and methods of investigation: the research covers the period 2020-2025. 48 patients with fractures of the hand and paw bones were observed in the traumatology department of the multidisciplinary clinic of the Center for the Development of Professional Qualifications of Medical Workers. Of these, 42 (87.5%) were men and 6 (12.5%) were women. Their average age was 29.9 years. All patients underwent clinical, laboratory, radiological and MRI examinations (Table 1).

Table 1

Distribution of patients by age and sex, n=48

Group	Age	Sex		%
		Male <i>abc, %</i>	Female <i>abc, %</i>	
Destruction by age	18-30	22 (45,8%)	4 (8,3%)	26 (54,1%)
	31-40	11 (22,9%)	1(2,1%)	12 (25,0%)
	41-50	8 (16,7%)	1(2,1%)	9 (18,8%)
	51-60	1(2,1%)	-	1 (2,1%)
TOTAL		42 (87,5%)	6 (12,5%)	48 (100%)

In 35 (72.9%) patients, the bones of the right hand were damaged, and in 13 (27.1%) the bones of the left hand were damaged. Types of injuries received among patients: domestic trauma in 30 (62.5%) patients, industrial trauma in 9 (18.7%) patients, sports trauma in 6 (12.5%) patients, and criminal trauma in 3 (6.25%) patients (table 2).

Table 2

Type of trauma Area	Domestic trauma	Industrial trauma	Sport trauma	Criminal trauma	Total
Bones of the right hand paw	23 (47,9%)	6 (12,5%)	4 (8,3%)	2 (4,2%)	35 (72,9%)
Left hand paw bones	7 (14,6%)	3 (6,2%)	2 (4,2%)	1 (2,1%)	13 (27,1%)
Total	30 (62,5%)	9 (18,7%)	6 (12,5%)	3 (6,3%)	48 (100%)

Patients were classified by the duration of injury: 9 (18.8%) patients presented within 1 month, 32 (66.6%) patients presented between 1 and 3 months, and 7 (14.6%) patients presented more than 3 months (Figure 1).

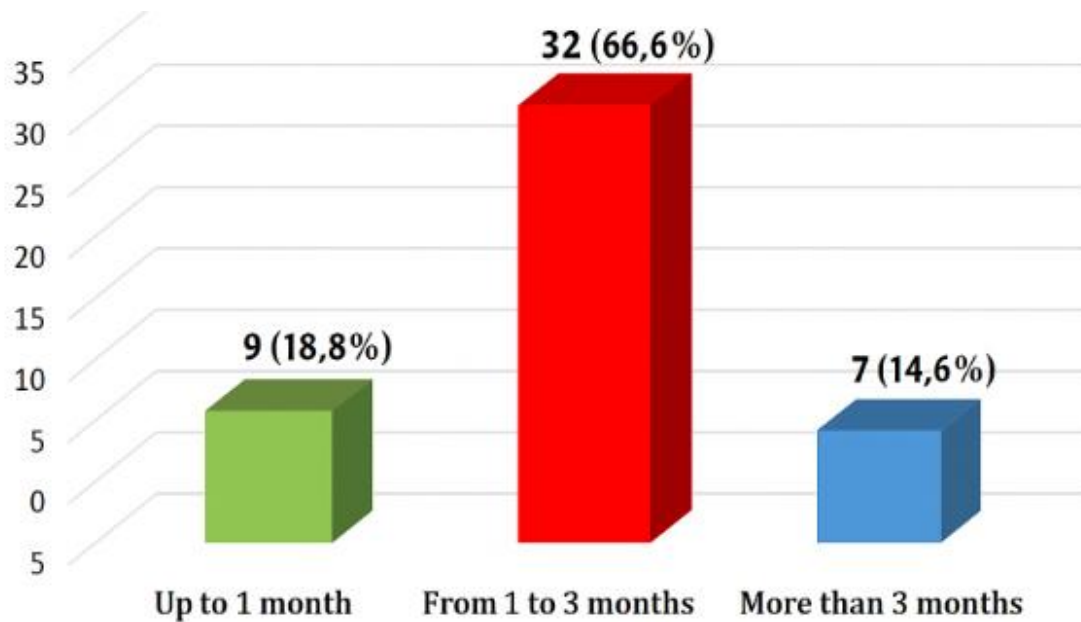


Figure 1. Distribution by duration of injury.

In the treatment of fractures of the phalanges of the hand paw, the use of the Ilizarov mini-fixator with interosseous osteosynthesis provides stable fixation and the possibility of early rehabilitation. The Ilizarov mini-apparatus consists of two units, a node.

Clinical examples:

1) Patient: U.A., 18 years old. 2 weeks ago, he had a history of trauma as a result of a blow to a hard object. Diagnosis: Closed fracture of the middle third of the diaphysis of the IV-V metacarpal bones of the right hand with displacement of bone fragments. Operation: Open reduction and fixation of the fracture of the middle third of the diaphysis of the IV-V metacarpal bones of the right hand with the help of the Ilizarov mini-fixator apparatus (Fig. 2).

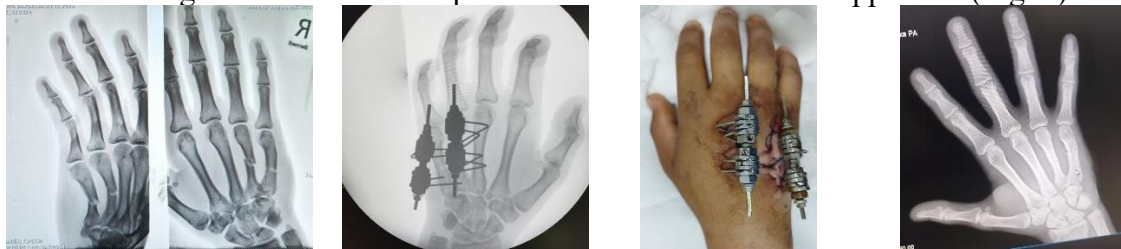

Figure 2. Before the operation

Operation process

Condition after receiving the device

The postoperative period was uneventful. 6 days after the operation, exercise therapy was prescribed. The long-term outcome was assessed as good after one year.

2) Patient: M.M., 29 years old. A week before the anamnesis, he had a trauma from hitting his hand against a wall. Diagnosis: Fracture of the V-metacarpal bone of the left hand below the closed head, with displacement of bone fragments. Operation: Fracture of the V-

metacarpal bone of the left hand below the head, open reduction and fixation with the Ilizarov mini-fixator apparatus (Fig. 3).

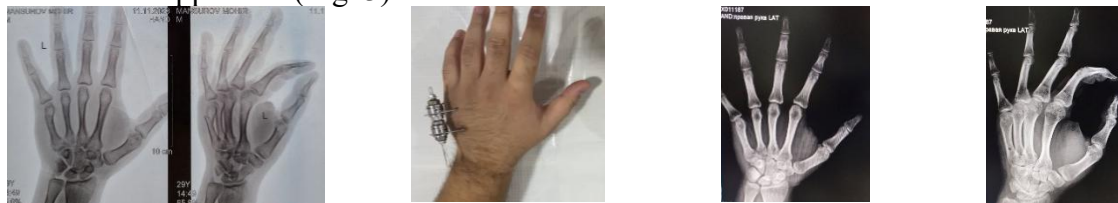

Figure 3. Before the operation

Operation process

Condition after receiving the device

The postoperative period was uneventful. 5 days after the operation, exercise therapy was prescribed. The long-term result was assessed as good after one year.

3) Patient B.R., 35 years old. According to the anamnesis, 20 days ago, he suffered a trauma from a blow to a hard object. Diagnosis: Closed fracture of the middle third of the middle phalanx of the left hand IV - finger with displacement of bone fragments. Operation: Open reduction of the fracture of the middle third of the middle phalanx of the left hand IV - finger and fixation using the Ilizarov mini-fixator (Fig. 4).

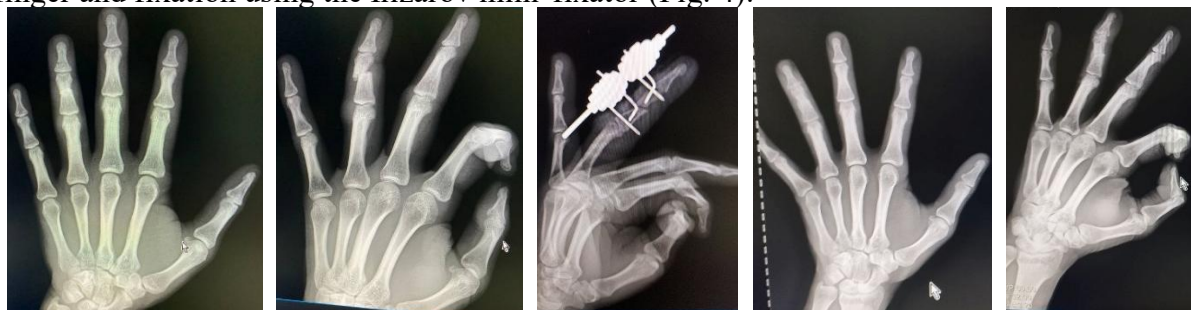

Figure 4. Before the operation

Operation process

Condition after receiving the device

The postoperative period was uneventful. 5 days after the operation, physical therapy was prescribed. The long-term outcome was assessed as good after two years.

Results: Treatment of fractures of the hand and paw bones using the Ilizarov mini-fixator apparatus leads to early bone consolidation processes, a decrease in the risk of post-traumatic contractures, and a reduction in rehabilitation time. During the study, we studied the anatomical and functional results of 48 patients in the short and long-term periods from 6 months to 5 years after the end of treatment. According to Zurmaeva I.A., the results were assessed on a three-point system. It looks like this: - good - in 37 (77.1%) patients, - satisfactory - in 10 (20.8%) and unsatisfactory - in 1 (2.1%) patient. The unsatisfactory result was due to the development of secondary infection around the sutures, which led to the removal of the device and the transfer to a plaster cast.

Conclusion: Thus, our experience in using the Ilizarov mini-apparatus in the treatment of fractures of the phalanges of the hands demonstrates its great potential both in terms of repositioning and fixation of bone fragments and in terms of their functional restoration. The method of treating fractures of the phalanges of the hands and feet with the Ilizarov mini-apparatus is the most effective method, allowing to achieve high stability of the fractured bone

fragments, reduce recovery time and reduce complications. The choice of this method in complex and unstable fractures ensures accurate repositioning and fixation. All of the above allows us to recommend this treatment method for wider implementation in clinical practice for the rehabilitation of patients with this complex category of injuries.

References:

1. Азолов В.В., Александров Н.М. Эффективность реконструкции пальцев кисти при последствиях травм различной этиологии // Вестник травматологии и ортопедии – 2021. – № 2. – С. 82–88.
2. Афанасьев, Л. М. Сравнительная оценка различных методов лечения переломов трубчатых костей кисти // Травматология и ортопедия России. - 2018. - № 2. - С. 13-15.
3. Бейдик О.В., А.В.Зарецков, К.Г.Бутовский. Особенности лечения пациентов с повреждением костей кисти / Вестник ТГУ, Россия, г.Томск., т 16, выпуск 5, 2021, стр.1376-1382.
4. Витюгов, И. А. Консервативное и оперативное лечение внутри- и околосуставных переломов V пястной кости кисти // Лечение больных с повреждениями суставов и их последствиями. Л., 2019. - С. 23-26.
5. Копысова В.А., А.М. Мироманов, Д.П. Селиванов./ Лечение больных с неосложненными переломами костей кисти в амбулаторных условиях// Журнал Гений Ортопедии № 3, Россия, Курган, стр.76-80. 2014 г.
6. Коршунов, В. Ф. Лечение переломов пястных костей кисти методом стабильного интрамедуллярного остеосинтеза штифтами из никелида титана // Патология кисти : сб. науч. тр. – СПб, 2022. - С. 21-24.
7. Мигулева, И. Ю. Первый опыт лечения закрытых переломов пястных костей с применением короткой гипсовой повязки // Вестн. травматологии и ортопедии им Н. Н. Приорова. 2022. № 2. – С .30-33.
8. Начкебия Л. Н., Шихалева Н. Г., Климов О. В., Тягунов Д. Е. Применение метода чрескостного дистракционно-компрессионного остеосинтеза минификсатором Илизарова при переломах V пястной кости кисти. Молодой ученый. 2020; №8(298), стр.76–78.
9. Нухов А. Р. и соавт. «Мини-аппарат Илизарова при переломах метакарпальных костей» — обзор/практическое руководство (онлайн-статья/клинический разбор). 2022, №4, стр.112–118.
10. Швед С.И., Ю.М. Сысенко, С.И. Новичков, А.А. Свешников и др. Чрескостный остеосинтез мини-фиксатором Илизарова при переломах костей кисти: Отчет о НИР (закл.). – Курган, 2020. – 71 с.
11. Шевцов В. И. и соавт. Чрескостный остеосинтез мини-аппаратом Илизарова при лечении больных с переломами трубчатых костей кисти Журнал «Гений ортопедии» 2021. №3, стр.171–175.
12. Шихалёва Н.Г., И.В. Чиркова. Лечение больных с закрытыми переломами дистального метаэпифиза пястных костей с применением чрескостного остеосинтеза// Журнал Гений Ортопедии № 2, Россия, Курган, стр.40-45. 2022 г.
13. El-Shaer AF, Shams El-Deen AF, El-Deen Abu Hussein AS, Neena HA. Functional outcome of mini external fixator in hand injuries. Int J Orthop Res Open. 2023/2024 (PDF).



14. Li X, Wang Y, Zhang Z, et al. Biomechanical study of a modified application of Ilizarov external mini-fixator for metacarpal neck fractures: comparative analysis. *J Orthop Surg Res.* 2025; DOI:10.1186/s13018-025-05795-z.
15. Nippon J Med Sch / Minimally invasive corrective osteotomy with the Ilizarov mini-fixator for malunited phalangeal fractures: technical note/case series. / *Hand Surg Japan.* 2021–2022.
16. Novel A / Mini External Fixation Technique versus Percutaneous Fixation for Unstable Finger Fractures. *Clin Orthop/Hand Surg* (open access). 2023.
17. Zhu Y, Xu Y, Pu S, Lv Q, Cai X, et al. Metacarpal lengthening using a mini-ring Ilizarov device for thumb reconstruction. *J Hand Surg Am.* 2023.
18. Elmurotova D.B., Kattaxodjayeva D.U., Jaxongirova Sh.U., Yusupova M.B. Physics of remote gamma therapy // *Web of Discoveries: Journal of Analysis and Inventions*, V.3, Issue 4, ISSN(E): 2938-3773, P.50-54, April – 2025, Испания, <https://webofjournals.com/index.php/3/article/view/3880>
19. Elmurotova D.B., Shodiev A.A., Mussaeva M.A. Impact of electron radiation on resistivity in YBCO and GdBCO high-temperature superconducting tapes // *Web of scientist: international scientific research journal*, ISSN: 2776-0979, V.6, Issue 5, may-2025, P.161-173, Indonesia, <https://wos.academiascience.org/index.php/wos/article/view/2672>
20. Elmurotova D., Fayziyeva N.A., Bozorov E.H. History of the discovery of radioactivity and x-rays, nuclear explosions explanation of the phenomenon research using interactive methods // *Web of Discoveries: Journal of Analysis and Inventions*, V.3, Issue 5, ISSN(E): 2938-3773, P.61-65, May-2025. Испания <https://webofjournals.com/index.php/3/article/view/4233>
21. Elmurotova D.B., Ro‘zimatova Sh.Sh., Umarova F.S. Insonning estetik tafakkuri // *Лучшие интеллектуальные исследования*, ISSN:3030-3680, Ч.45, Т.1, С.130-135, май-2025, Россия. scientific-jl.com/luch/.
22. Elmurotova D.B., Farmonova Sh.Sh., Umarova F.S. Borliq va bo‘shliq: mavjudlik chegaralari haqida tafakkur // *Лучшие интеллектуальные исследования*, ISSN:3030-3680, Ч.44, Т.5, С.411-416, май-2025, Россия. scientific-jl.com/luch/.
23. Elmurotova D.B., Jo‘rayeva R.A, Umarova F.S. “Bilimning chegarasi va rad etilishi”: eskeptitsizm va bilimga bo‘lgan ishonchsizlik muammosi // *Лучшие интеллектуальные исследования*, ISSN:3030-3680, Ч.44, Т.5, С.417-423, май-2025, Россия. scientific-jl.com/luch/.
24. Elmurotova D.B., Umarova F.S., G‘uzorova O.U. Hayot va o‘lim chegarasida: bioetikaning zamonaviy tibbiyotdagi o‘rni // *Лучшие интеллектуальные исследования*, ISSN:3030-3680, Ч.44, Т.4, С.261-266, май-2025, Россия. scientific-jl.com/luch/.