



## **OPERATIONS FOR BENIGN TUMORS OF THE AURICLE. CLINICAL CASE**

**Lutfullaev Gairat Umrullaevich**

Doctor of Medical Sciences, Professor of the Department of Otorhinolaryngology, Faculty of Postgraduate Education, Samarkand State Medical University; Samarkand, Uzbekistan

**Safarova Nasiba Iskandarovna**

Candidate of Medical Sciences, Assistant of the Department of Otorhinolaryngology, Faculty of Postgraduate Education, Samarkand State Medical University; Samarkand, Uzbekistan

**Isaeva Zarinakhon Abdullaevna**

Master of the 1st year of the Department of Otorhinolaryngology, Faculty of Postgraduate Education, Samarkand State Medical University; Samarkand, Uzbekistan

**Khalilov Muhridin Oripovich**

Clinical resident of the Department of Otorhinolaryngology, Faculty of Postgraduate Education, Samarkand State Medical University; Samarkand, Uzbekistan

### **Abstract**

Surgical intervention for benign tumors has been and remains the main and almost the only method of treatment. Radiation treatment for these tumors is used extremely rarely. This is more often the exception than the rule.

**Keywords:** benign tumors, surgery, external ear tumor

### **Introduction**

The number of patients with ear tumors has been gradually and steadily increasing over the past 15-20 years. The localization of these neoplasms, compared to other initial localizations within the ENT organs, is not fully understood, despite the increased interest in ear neoplasms over the past decades, mainly from otolaryngologists.

Very often, discussions revolve around ENT oncology, implying exclusively malignant tumors, while forgetting about benign neoplasms, which are almost 10 times more common in frequency than malignant ones. Many of these benign tumors clinically behave like malignant tumors, exhibiting destructive growth and a tendency for frequent recurrences.

A whole range, if not all, of these tumors are prone to malignancy, and in this aspect, they should be considered facultative or sometimes obligatory precancerous conditions. Among benign formations, there is a large and widespread group of pathological processes that are collectively referred to as tumor-like formations.

There is no clear boundary not only in clinical presentation but also in morphological structure between tumor-like formations and benign tumors of the external ear, as well as often between benign and malignant neoplasms. Early manifestations of tumor-like formations and benign tumors of the external ear and periauricular region, especially those originating from the middle ear, are insufficiently studied and almost unknown to a wide range of practicing physicians. New highly informative research methods that have proven effective in other localizations of tumors have not yet found widespread use in neoplasms of the external ear and periauricular region. They are not adapted for tumor lesions of the auditory analyzer, and their informative value in this localization of the pathological process is not defined.

This can also be noted when discussing the treatment of patients with tumors of the external ear, the methods of surgical interventions, and efforts to increase the effectiveness of treatment (improving existing methods, developing new ones, searching for effective combinations: surgery, cryodestruction, laser therapy, and pharmacological protection of microorganisms).

The fight against tumor formations in general (of the auditory analyzer in particular) should begin not when the first signs of malignant tumors appear, but long before their appearance. It should start with the identification and, if possible, exclusion of risk factors, the elimination of background processes and conditions, the timely detection and elimination of pre-tumor processes, including tumor-like formations and benign tumors.

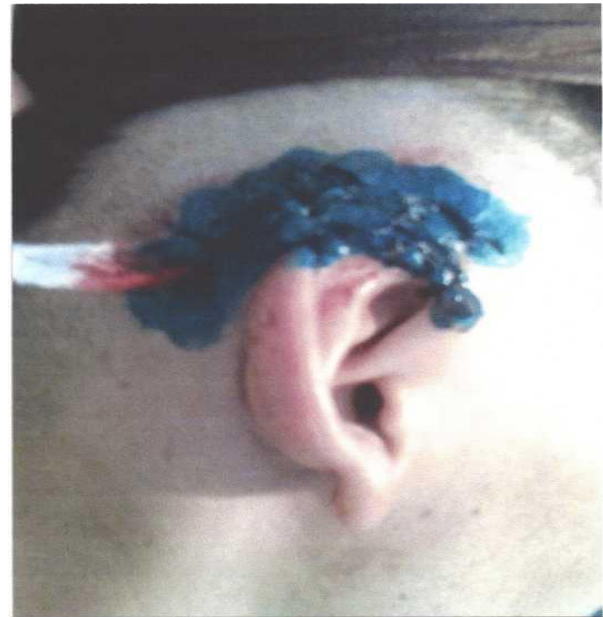
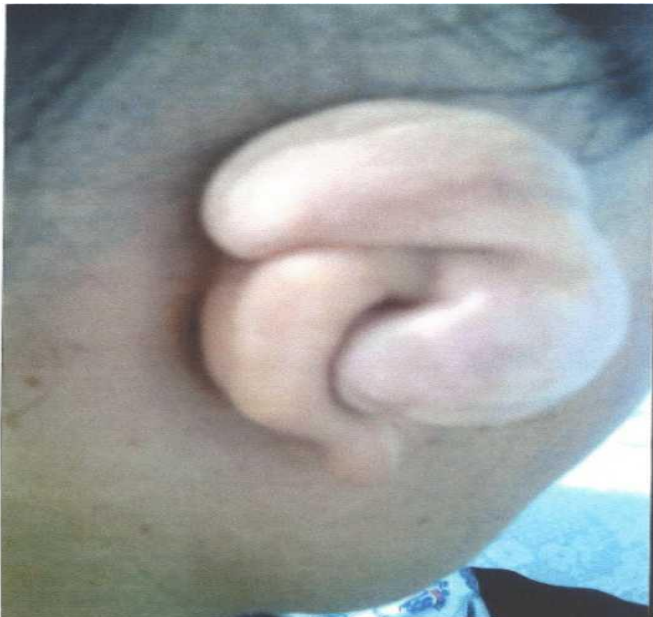
## **Discussion**

Timely detection of tumor-like formations and benign tumors of the external ear, as well as their early removal, should be considered not only as preservation or restoration of the functional state of the ear, but also as an effective way to prevent the development of malignant tumors, in other words, as a prevention of this disease. The main method of treating patients with tumors and tumor-like formations is surgical, as well as various combinations of surgical intervention with the use of extremely low temperatures. Timely removal of a benign tumor is one of the reliable and effective forms not only of treatment but also of prevention of their malignancy. The variety of forms and locations of these tumors determines the variety of surgical interventions.

### **Surgical steps:**

The removal of the neoplasm on the auricle was performed without involving the underlying cartilage. After examining the tumor under a microscope and confirming the absence of signs of malignancy, the tumor could be removed. Localized tumors (stage I-II) were removed under local anesthesia, and an adrenaline test was conducted. This test involved intradermal injection of novocaine with the addition of adrenaline. Under the influence of adrenaline and by compressing the blood vessels through infiltration with novocaine, the vessels narrowed, and the skin paled. The pale areas of skin around the tumor and the tumor itself were examined under a microscope, focusing on the vascular pattern and the surface condition of the tumor. By comparing the microscopic image of the vascular pattern before and after the injection of novocaine with adrenaline, the vascular reaction to adrenaline was assessed. Then novocaine was injected subperiosteally, attempting to hydraulically detach it (the periosteum) along with the tumor and skin from the cartilage. A free hydraulic detachment of the tumor from the cartilage without novocaine seepage through the tumor tissue to the surface is a good sign of intact periosteum integrity and cartilage integrity. If both the periosteum and cartilage are affected, hydraulic detachment of the periosteum along with the tumor and skin is not successful. After free detachment of the tumor with skin and periosteum from the underlying cartilage, the tumor could be removed within healthy tissues without cartilage resection. The strip of healthy skin around a benign tumor should not exceed 3mm. In diffuse cavernous hemangiomas and other vascular tumors where the border of the pathological focus is unclear, it is better to increase the width of this strip to 5mm or more.

The surface of the cartilage at the bottom of the wound, after tumor removal, was also examined under a microscope (despite a positive hydraulic test). The surface of the unaffected by the tumor cartilage was smooth and shiny. If it was not possible to bring the wound edges together and suture the skin, we left the wound open. It healed by secondary intention. Here is one such observation:



### **Before and after surgery**

#### **Clinic Case**

Patient E., 28 years old, was admitted to the clinic due to a tumor on the auricle with complaints of ear deformation and its enlargement. Over 3 years ago, a soft nodule appeared on the posterior inner surface of the auricle, in the curl area. Within 2 years, several more nodules appeared near the first one. The auricle began to increase in thickness in this area. The patient sought medical attention and was hospitalized at the ENT department of the I Clinic of Samara State Medical University.

The patient does not recall any childhood illnesses. Throughout his life, he only had the flu a few times. Prior to this current illness, he had never been treated in a hospital. Examination of internal organs did not reveal any pathologies.

The right auricle is significantly larger than the left one. The curl and a large part of the posterior surface of this auricle are bumpy, with pulsation noticeable across its entire bumpy surface. The skin above the new growth is unchanged, normal in color, and painless upon palpation. The thickened bumpy part of the auricle is soft and elastic in consistency, and its volume decreases when compressed. Pulsation of the auricle is clearly felt. The anterior surface of the auricle shows no pathological changes. The external auditory canal is clear, the eardrum is clean with all recognizable signs. No hearing impairments were detected in the right ear. The boundaries of the new growth are not clear. Under the microscope, no pathological skin changes in the area of the lesion were found, except for a few areas with pathological changes in the vascular pattern.

The surgery was performed using Antoniv's method under local anesthesia with a 1% solution of novocaine with the addition of a 0.1% solution of adrenaline. An adrenaline test was not conducted. The hydraulic test was immediately started to determine the condition of the

cartilage and cartilage of the right auricle. The cartilage was easily detached by introducing a solution underneath it. Following this, a skin and cartilage incision was made along the curl, along its posterior surface, deviating 0.5 cm from the edge of the tumor. Bleeding during the incision was normal. The incision was made along the tumor through healthy skin. The scar on the skin after the first attempt to remove the tumor was located in the center of the tumor focus. After ensuring that the posterior surface of the auricular cartilage and the bone tissue of the surface of the mastoid process were smooth and shiny, we detached the edges of the skin on the mastoid process and on the curl of the auricle. The auricle was as if sewn to the mastoid process. The auricle appeared flattened, attached to the mastoid process.

Resection of the auricle for benign tumors, let alone its removal, is rarely performed. These surgeries are indicated for tumors spreading to the cartilaginous framework, if it is not possible to detach the cartilage and skin on the opposite side of the auricle.

### Conclusion

The main method of treating patients with tumors and tumor-like formations is surgical, as well as various combinations of surgical intervention with the use of extremely low temperatures. Timely removal of benign tumors is one of the reliable and effective forms not only of treatment, but also of prevention of their malignancy. The variety of forms and locations of these tumors determines the variety of surgical interventions.

### References:

1. Grant DA, Finley ML, Coers CR., 3rd Early management of the burned ear. *Plast Reconstr Surg.* 1969;44:161–166.
2. Purdue GF, Hunt JL. Chondritis of the burned ear: a preventable complication. *Am J Surg.* 1986;152:257–259.
3. Kim JK, Eom DS, Jang EK, Kim YB, Cho CS, Yang KH, et al. A clinical evaluation of chondritis in the burned ear. *Korean J Otolaryngol-Head Neck Surg.* 1992;35:717–722.
4. Bojanović M, Zivković-Marinkov E, Veselinović D, Bojanović A, Vucković I. [Malignant tumors of auricula and periauricular area] *Vojnosanit Pregl.* 2009;66:611–616.
5. Lee SH, Jun BC, Lee DH, Cho KJ. A case of enchondral pseudocyst of the auricle. *Korean J Otorhinolaryngol-Head Neck Surg.* 2007;50:713–715.
6. Ozcan KM, Dere H, Ozcan I, Gun T, Unal T. An epidermal cyst in the parotid gland following ear surgery: a case report. *B-ENT.* 2006;2:193–195.
7. Urioste SS, Arndt KA, Dover JS. Keloids and hypertrophic scars: review and treatment strategies. *Semin Cutan Med Surg.* 1999;18:159–171.
8. Muir IF. On the nature of keloid and hypertrophic scars. *Br J Plast Surg.* 1990;43:61–69.
9. Niessen FB, Spauwen PH, Schalkwijk J, Kon M. On the nature of hypertrophic scars and keloids: a review. *Plast Reconstr Surg.* 1999;104:1435–1458.
10. Cosman B, Crikelair GF, Ju DMC, Gaulin JC, Lattes R. The surgical treatment of keloids. *Plast Reconstr Surg.* 1961;27:335–358.
11. Larrabee WF, Jr, East CA, Jaffe HS, Stephenson C, Peterson KE. Intralesional interferon gamma treatment for keloids and hypertrophic scars. *Arch Otolaryngol Head Neck Surg.* 1990;116:1159–1162.



12. Griffith BH, Monroe CW, McKinney P. A follow-up study on the treatment of keloids with triamcinolone acetonide. *Plast Reconstr Surg.* 1970;46:145–150.
13. Chowdri NA, Masarat M, Mattoo A, Darzi MA. Keloids and hypertrophic scars: results with intraoperative and serial postoperative corticosteroid injection therapy. *Aust N Z J Surg.* 1999;69:655–659.
14. Covelli E, De Seta E, Zardo F, De Seta D, Filipo R. Cavernous haemangioma of external ear canal. *J Laryngol Otol.* 2008;122:e19.
15. Ol'shanskii MS, Korotkikh NG, Shcherbinin AS, Stepanov IV. [Combined treatment of auricular vascular neoplasms] *Vestn Otorinolaringol.* 2008:48–50.
16. Ahmad I, Das Gupta AR. Epidemiology of basal cell carcinoma and squamous cell carcinoma of the pinna. *J Laryngol Otol.* 2001;115:85–86.
17. Albright SD., 3rd Treatment of skin cancer using multiple modalities. *J Am Acad Dermatol.* 1982;7:143–171.
18. Bridges MN, Doval M. Cutaneous squamous cell carcinoma of the external auditory canal. *Dermatol Online J.* 2009;15:13.